

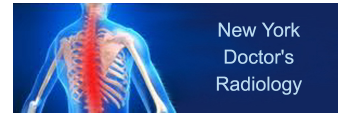

Your Logo Here

Structured
Ultrasound
Reporting

New York Doctor's Medical Center

56 Berent Ave. New York, NY 07002
Tel: 212-541-1900 Fax: 212-541-1199



Your Logo Here

Abdominal Report

Signed Final 03/25/2011 12:48 pm

Patient Info

ID #: 11223344 Name: Michael H Smith D.O.B.: 02/03/69 (42 yrs) Date: 03/25/2011 12:23 pm

Performed By

Performed By: Gary Richards Referred By: Mark Firestone MD
Attending: James E. Stark, MD

Procedures

Abdomen Complete
Retroperitoneal Complete

Indications

Pain RUQ
Vomiting

Technique/Scan Quality

Scan Quality: Satisfactory

Liver

Right Lobe Length: 10.0 cm
Echogenicity/Echotexture: Normal
Portal Veins: Normal Appearance Hepatic Veins: Normal Appearance

Gallbladder

Cholelithiasis: Single, mobile stone Focal Tenderness: Murphy's Sign present
Wall Thickness: Mild Thickening measuring: 3mm

Biliary Tract

Intrahepatic Ducts: No dilatation visualized
Extrahepatic Ducts: No dilatation visualized
Common Duct: 5.0 mm

Pancreas

Head: Within normal limits Body: Within normal limits
Tail: Within normal limits Uncinate Process: Poorly visualized
Duct: No abnormality visualized

Spleen

Size (cm) L: 12.0 AP: 3.0 TV: 7.0 Vol (ml): 131.9
Comment: No abnormality visualized

Right Kidney

Size (cm) L: 11.0 AP: 5.0 TV: 5.0

Lesions

| # | Date | Location | Description | L(cm) | AP(cm) | TV(cm) |
|---|----------|------------|---------------|-------|--------|--------|
| 1 | 03/25/11 | Upper Pole | Cyst - simple | 3.1 | 2.0 | 2.1 |
| 2 | 03/25/11 | Upper Pole | Cyst - simple | 3.0 | 2.1 | 2.0 |

Left Kidney

Size (cm) L: 11.0 AP: 5.0 TV: 5.0

Cortical Thickness: Normal
Cortical Echogenicity: NormalHydronephrosis: Normal
Ureter: Not visualized**Aorta****Measurements (cm):**

| | | |
|----------|---------|---------|
| Proximal | AP: 2.5 | TV: 2.5 |
| Mid | AP: 2.0 | TV: 2.0 |
| Distal | AP: 1.5 | TV: 1.5 |

IVC

Normal in caliber, where visualized.


Fluid Collections

No fluid collections.

Impression

Abdominal ultrasound was performed. Normal appearing liver parenchyma, portal and hepatic veins. No intrahepatic or extrahepatic ductal dilatation. CBD measures 5.0 mm. Cholelithiasis with a single mobile stone. Gallbladder wall measures 3 mm. Positive Murphy's sign noted. The pancreatic head, body and tail appear normal. Normal appearing spleen measuring 12.0 x 3.0 x 7.0 cm. Right kidney measures 11.0 x 5.0 x 5.0 cm. There is a right upper pole renal cyst measuring 3.0 x 2.1 x 2.0 cm. Normal appearing left kidney measuring 11.0 x 5.0 x 5.0 cm. Normal appearing aorta and inferior vena cava with no enlarged lymph nodes seen. No fluid collections noted. Please correlate with clinical findings.

Thank you for sharing in the care of Ms. Michael H Smith with us.

**James Stark, MD****Electronically Signed Final Report 03/25/2011 12:48**